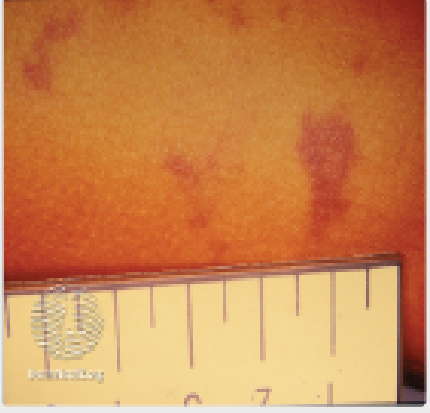


Paediatric rashes of concern

Purpura



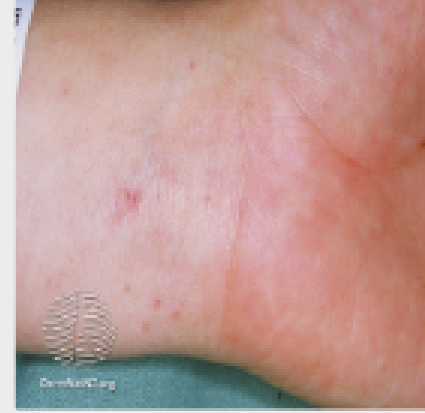Photograph courtesy of DermNet NZ
<https://dermnetnz.org>

- Appears as large (greater than 2mm) non-blanching purple spots or an unexplained bruise.
- It may indicate a serious bacterial infection such as Meningococcal.

⚠ Alerts

- Have an urgent medical review for consideration of antibiotics for treatment.
- If Meningococcal is suspected, it must be reported as a notifiable disease.

Petechiae



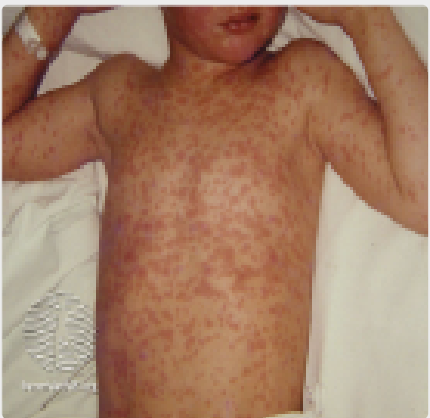Photograph courtesy of DermNet NZ
<https://dermnetnz.org>

- Presents as non-blanching pinpoint spots.
- When associated with fever it can be caused by several conditions including Meningococcal, Streptococcus pneumoniae, Haemophilus influenzae or other viruses.

⚠ Alerts

- Have an urgent medical review for consideration of antibiotics for treatment.
- If Meningococcal is suspected, it must be reported as a notifiable disease.

Measles



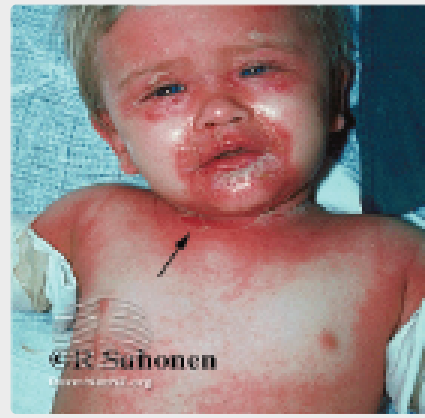Photograph courtesy of DermNet NZ
<https://dermnetnz.org>

- Red, blotchy and blanching
- Appears first on the face later spreading to the trunk and then generalised.
- Usually accompanied by any of the following: irritability, conjunctivitis, a runny nose, a dry cough or koplik's spots (white lesions on the buccal mucosa).
- Caused by the measles virus. Transmitted by the airborne route.

⚠ Alerts

- Measles is highly infectious spread by respiratory droplets.
- Suspected measles requires immediate negative pressure isolation.
- Measles is a notifiable disease.

Staphylococcus Scalded Skin Syndrome



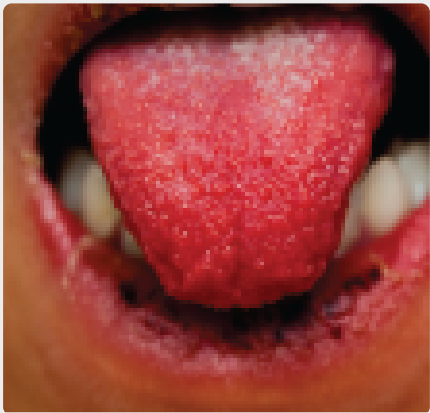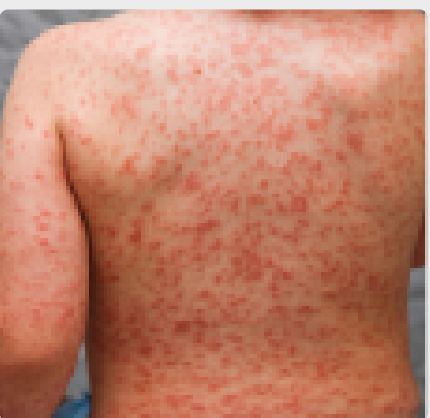Photograph courtesy of DermNet NZ
<https://dermnetnz.org>

- Presents as red blistering skin that looks similar to a burn or scald.
- Usually accompanied by fevers and irritability.
- Caused by release of exotoxins from toxigenic strains of bacteria Staphylococcus aureus.

⚠ Alerts

- Have an urgent medical review.
- Requires timely administration of antibiotics.

Kawasaki Disease



Photographs courtesy of Kawasaki Disease Foundation

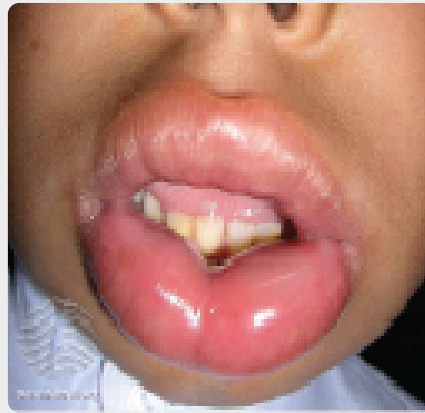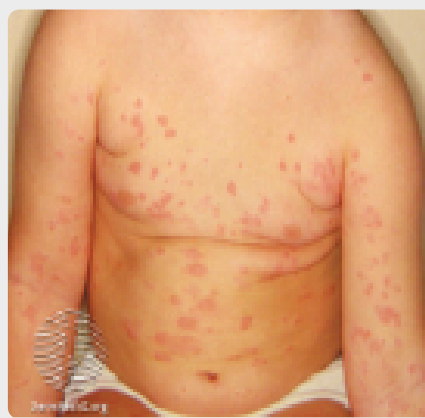- Red, blotchy and blanching rash (trunk, limbs and nappy area)
- 'Strawberry Tongue' - a red lumpy tongue
- Dry red or cracked lips
- Bloodshot eyes with no discharge
- Swelling to hands and feet with redness to palms and soles. Peeling skin around the fingernails may occur later in the course of the illness.
- Swollen neck glands

Unknown cause. Most common in children under 5 years of age. Can occur in children of all ethnic origins. Most common in children of Asian descent.

⚠ Action

Urgent medical review to confirm diagnosis to ensure timely treatment using intravenous immunoglobulin (IVIG).

Urticaria and Angioedema



Photographs courtesy of DermNet NZ
<https://dermnetnz.org>

Urticaria

- Commonly referred to as hives.
- Affects the skin layers (epidermis and dermis) and appears as slightly raised red patches on top of the skin.
- Can occur anywhere on the body.
- Patches can be both very itchy and painful.

Angioedema

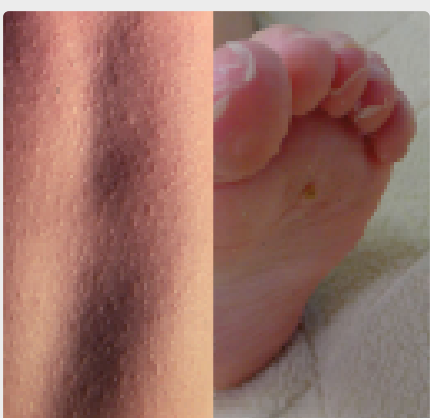
- Affects the tissues beneath the skin (subcutaneous tissues) and mucous membranes causing redness and swelling.
- Can affect areas such as ears, eyelids and genitals.
- Most concerning, it can affect the lips, tongue and throat causing airway compromise.

⚠ Alerts

Urticaria when associated with any of the following can indicate life threatening anaphylactic shock.

- swelling (angioedema) to the tongue
- lips or throat (child may complain of tightness)
- difficulty breathing, stridor, cough or wheezing
- difficulty talking, drooling or difficulty swallowing/ managing secretions
- altered level of consciousness
- pale and floppy

Scarlet Fever



Photographs courtesy of DermNet NZ
<https://dermnetnz.org>

- Can present as a diffuse rash that is pink-red, with "pinhead" spots.
- Can feel sandpaper-like.
- Most often develops after the onset of other symptoms including fever, headache, lethargy, vomiting and abdominal pain.
- Scarlet fever can occur as a result of a Group A streptococci bacterial infection.

⚠ Alerts

- Have an urgent medical review.
- Requires timely administration of antibiotics.



This poster was adapted from the Children's Health Hospital and Health Service - Queensland Paediatric Emergency Care Skill Sheet - Rashes in Children. For more information, please scan the QR code.

Metro North Health



Queensland Government